

Intersex Genital Mutilations Human Rights Violations Of Children With Variations Of Sex Anatomy



**HUMAN
RIGHTS FOR
HERM
APHRODITES
TOO !**

**NGO Report
to the 2nd Periodic Report of South Africa
on the Convention on the Rights of the Child (CRC)**

Compiled by:

StopIGM.org / Zwischengeschlecht.org (International Intersex Human Rights NGO)

Markus Bauer
Daniela Truffer

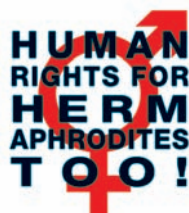Zwischengeschlecht.org
P.O.Box 2122
CH-8031 Zurich

info_at_zwischengeschlecht.org
<http://Zwischengeschlecht.org/>
<http://StopIGM.org/>

15 August 2016

This NGO Report online:

<http://intersex.shadowreport.org/public/2016-CRC-ZA-NGO-Zwischengeschlecht-Intersex-IGM.pdf>



Executive Summary

South Africa is in breach of its obligations under the Convention on the Rights of the Child to **(a) take effective legislative, administrative, judicial or other measures to prevent harmful practices, i.e. non-urgent, unnecessary surgery and other medical treatment carried out on intersex children** without the effective, informed consent of those concerned, causing severe mental and physical pain and suffering, and **(b) to ensure impartial investigation, access to redress, and the right to fair and adequate compensation and rehabilitation for victims.** (Art. 24 para. 3 in conjunction with CRC/CEDAW Joint General Comment No. 18/31 “on harmful practices”). (A)

This Committee has already recognised IGM practices as a breach of the Convention in previous **Concluding Observations** for Switzerland, Chile, Ireland, France, the UK and Nepal, and called to **(a)** guarantee bodily integrity, autonomy and self-determination to children concerned, **(b)** adopt legal provisions to ensure redress and compensation, and **(c)** provide access to free counselling. (A)

Also **CAT, CEDAW, CRPD**, the UN Special Rapporteur on Torture (**SRT**), the UN High Commissioner for Human Rights (**UNHCHR**), the World Health Organisation (**WHO**) and the Council of Europe (**COE**) call for **legislative remedy** and **access to redress and justice** for victims.

Intersex people are born with **Variations of Sex Anatomy**, including atypical genitals, atypical sex hormone producing organs, atypical response to sex hormones, atypical genetic make-up, atypical secondary sex markers. While intersex people may face several problems, in the “developed world” the most pressing are the ongoing **Intersex Genital Mutilations**, which present a distinct and unique issue constituting significant human rights violations.

IGM Practices include **non-consensual, medically unnecessary, irreversible, cosmetic genital surgeries, and/or other harmful medical treatments** that would not be considered for “normal” children, without evidence of benefit for the children concerned, but justified by societal and cultural norms and beliefs. **Typical forms** of IGM include “masculinising” and “feminising”, “corrective” genital surgery, sterilising procedures, imposition of hormones, forced genital exams, vaginal dilations, medical display, human experimentation and denial of needed health care (A).

IGM Practices cause known **lifelong severe physical and mental pain and suffering**, including loss or impairment of sexual sensation, painful scarring, painful intercourse, incontinence, urethral strictures, impairment or loss of reproductive capabilities, lifelong dependency on artificial hormones, significantly elevated rates of self-harming behaviour and suicidal tendencies, lifelong mental suffering and trauma, increased sexual anxieties, less sexual activity, dissatisfaction with functional and aesthetic results.

All typical IGM forms are still practised in South Africa today. Parents and children are misinformed, kept in the dark, sworn to secrecy, kept isolated and denied appropriate support. (A, B).

For more than 20 years, intersex people have criticised IGM as **harmful** and **traumatising**, as a form of **genital mutilation** and **child sexual abuse**, as **torture or ill-treatment**, and called for legislation to prevent it and to ensure remedies.

This **Thematic NGO Report** has been compiled by the international intersex NGO **StopIGM.org / Zwischengeschlecht.org**. It contains **Concluding Recommendations** (C).

**NGO Report
to the 2nd Periodic Report of South Africa
on the Convention on the Rights of the Child (CRC)**

Contents

IGM Practices in South Africa

Executive Summary 3

Introduction 5

A. IGM Practices in South Africa 7

1. Lack of Protection for Intersex Persons, IGM Practices Remain Pervasive 7

 a) Overview 7

 b) Most Common IGM Forms advocated by SA Medical Associations and Doctors 7

 c) Examples of South African IGM University Children’s Clinics 10

 d) Infant Victims of “Muti” Genital Mutilations 11

 e) Harmful Practices on Intersex Children outside Health Care Settings 11

 f) SA Doctors & Government consciously dismissing Human Rights Concerns 12

2. The Treatment of Intersex Children in SA as Harmful Practice and Violence 13

 a) Harmful Practice 13

 b) Violence against Children 14

3. Lack of Legislative Provisions, Impunity of the Perpetrators. 14

4. Obstacles to Redress and Compensation 15

B. Conclusion 16

C. Recommendations 17

Introduction

State Report and Intersex in South Africa

South Africa will be considered for its second periodic review by the Committee on the Rights of the Child during its 73rd Session in 2016. In South Africa, **doctors in public, university and private clinics** are regularly performing **IGM practices**, i.e. non-consensual, medically unnecessary, irreversible cosmetic genital surgeries, sterilising procedures, and other harmful treatments on intersex children, which have been described by survivors as genital mutilation and torture. IGM practices are known to cause severe, lifelong physical and psychological pain and suffering, and have been repeatedly **recognised by this Committee** and other **UN bodies** as constituting a **harmful practice, violence and torture or ill-treatment**.

Unfortunately, harmful practices on intersex children weren't mentioned in the State Report. However, this NGO Report demonstrates that the current, involuntary **medical treatment of intersex infants and children in South Africa** constitutes a harmful practice and a serious breach of South Africa's obligations under the Convention on the Rights of the Child.

South Africa not only does nothing to prevent this abuse, but in fact directly finances it via funding the public university clinics and paediatric hospitals, thus violating its duty to prevent harmful practices. To this day, **against better knowledge**, the South African Government **refuses to take appropriate legislative, administrative and other measures** to protect intersex children, and refuses survivors the right to justice, redress and compensation.

About the Rapporteurs

This NGO report has been prepared by the international intersex NGO *StopIGM.org / Zwischenengeschlecht.org*:

- **StopIGM.org / Zwischenengeschlecht.org**, founded in 2007, is an international Human Rights NGO based in Switzerland. It is led by intersex persons, their partners, families and friends, and works to represent the interests of intersex people and their relatives, raise awareness, and fight IGM Practices and other human rights violations perpetrated on intersex people, according to its motto, "*Human Rights for Hermaphrodites, too!*"¹ According to its charter,² *Zwischengeschlecht.org* works to support persons concerned seeking redress and justice, and has continuously collaborated with members of parliament and human rights bodies in order to call on Governments and Clinics to collect and disclose statistics of intersex births and IGM practices, and to prevent them. *StopIGM.org* has authored and co-authored several international thematic NGO reports resulting in concluding observations on IGM practices by CRC, CAT, CEDAW and CRPD.³

1 <http://Zwischengeschlecht.org/>, English pages: <http://StopIGM.org/>

2 <http://zwischengeschlecht.org/post/Statuten>

3 see <http://intersex.shadowreport.org>

Methodology

This thematic NGO report is a country-specific **addition to the thematic CRC NGO Reports for Switzerland (2014) and the UK (2016)** by partly the same rapporteurs.⁴

It is further based on publications by **Sally Gross / Intersex South Africa (ISSA)**,⁵ public personal testimony by **Nthabiseng Mokoena**,⁶ the **2016 ACHPR NGO report by Legal Resources Centre, Iranti-org and Gender Dynamix**,⁷ research by StopIGM.org, and personal communications with intersex people from South Africa.

Background: IGM Practices and Intersex Human Rights

Intersex Genital Mutilations are still an **“emerging human rights issue,”** unfortunately often neglected due to lack of access to comprehensive information. To assess the current practice at national level, some general knowledge on the matter is crucial. For more comprehensive information, the rapporteurs refer to the **thematic supplements in earlier thematic CRC NGO reports** (Switzerland, 2014 and the UK, 2016).⁸

The rapporteurs are aware that **IGM practices are a global issue, which can't be solved on a national level alone.** However, this report illustrates why **South Africa** is a State party to which it would be timely and appropriate to issue strong recommendations.

4 *2014 CRC Swiss Thematic NGO Report*, online: http://intersex.shadowreport.org/public/2014-CRC-Swiss-NGO-Zwischengeschlecht-Intersex-IGM_v2.pdf

2016 *CRC UK Thematic NGO Report*, online: http://intersex.shadowreport.org/public/2016-CRC-UK-NGO-Zwischengeschlecht-Intersex-IGM_v2.pdf

5 <http://www.intersex.org.za/>

6 <http://www.interfaceproject.org/nthabiseng-mokoena/>
<http://www.interfaceproject.org/transcript-nthabiseng-mokoena>
<http://intersexday.org/en/remembering-sally-south-africa/>

7 <http://genderdynamix.org.za/wp-content/uploads/ACHPR-Transgender-and-Intersex-Shadow-Report-April-2016.pdf>

8 “*IGM – Historical Overview*” and “*IGM – The 17 Most Common Forms*” contained in the *2014 CRC Swiss Thematic NGO Report*, online: http://intersex.shadowreport.org/public/2014-CRC-Swiss-NGO-Zwischengeschlecht-Intersex-IGM_v2.pdf

“*D. What is Intersex?*”, “*E. IGM Practices – Non-Consensual, Unnecessary Medical Interventions*”, “*F. The Treatment of Intersex Persons as a Violation of the Convention on the Rights of the Child*” and “*G. IGM in Medical Textbooks*” contained in the *2016 CRC UK Thematic NGO Report*, online: http://intersex.shadowreport.org/public/2016-CRC-UK-NGO-Zwischengeschlecht-Intersex-IGM_v2.pdf

A. IGM Practices in South Africa

1. Lack of Protection for Intersex Persons, IGM Practices Remain Pervasive

a) Overview

In **South Africa**, same as in the states of *Switzerland* (CRC/C/CHE/CO/2-4, paras 42-43), *Ireland* (CRC/C/IRL/CO/3-4, paras 39-40), *France* (CRC/C/FRA/CO/5, paras 47-48), *Chile* (UN CRC, CRC/C/CHL/CO/4-5, paras 48-49), the *United Kingdom* (CRC/C/GBR/CO/5, paras 45-46) and *Nepal* (CRC/C/NPL/CO/3-5, paras 41-42), there are **no legal or other protections** in place to ensure the rights of intersex children to physical and mental integrity, autonomy and self-determination, and to prevent non-consensual, medically unnecessary, irreversible surgery and other harmful treatments a.k.a. IGM practices.

To this day, the **South African government refuses to “take effective legislative, administrative, judicial or other measures”** to protect intersex children, but instead allows IGM practices to continue with impunity and against better knowledge.

To this day, all forms of **IGM practices remain widespread and ongoing**, advocated, prescribed and perpetrated by **doctors in public University, Regional Children’s Clinics, and Private Clinics**, and advocated by **South African medical associations**.

b) Most Common IGM Forms⁹ advocated by SA Medical Associations and Doctors

- **IGM 3: Sterilising Procedures** plus arbitrary imposition of hormones, as advocated in a 2001 paper¹⁰ by Rinus Wiersma (Principal Specialist for Paediatric Surgery, **University of KwaZulu-Natal**, Durban):¹¹

“Conclusion: It is suggested that, in Southern African true hermaphrodites, all ovotestes, discordant gonads, and all gonads that show only testicular tissue be excised as part of the initial corrective management.”

Similarly, in his 2011 thesis,¹² Wiersma reiterated:

“CONCLUSION [...] Ovotestes and testes still require early excision in children of both genders, and ovaries need excision only when the child is a male after the 7-8 year of age.”

Accordingly, at the Department of Paediatric Surgery, University of **KwaZulu-Natal**, Durban, from 1984-2006 a total of 111 children diagnosed with “*OvoTesticular DSD*” were mostly submitted to gonadectomies:¹³

“Gonadal surgery

[...] Fifty-nine patients had 20 gonads excised, but the results were not traceable / incomplete. The remaining 52 patients had a completely traceable histological record, showing that 83 gonads were removed in total, of which there were 74 ovotestes, seven ovaries and two testes. [...] The mean age at gonadectomy of the children was 7-months after the primary admission (range = 1-week to 8-years).”

9 For more information, see 2016 CRC UK NGO Report (p. 42-47), http://intersex.shadowreport.org/public/2016-CRC-UK-NGO-Zwischengeschlecht-Intersex-IGM_v2.pdf

10 Rinus Wiersma: “Management of the African child with true hermaphroditism”, *Journal of Pediatric Surgery* (2001), Volume 36, Issue 2, Pages 397-399, <http://dx.doi.org/10.1053/jpsu.2001.20726>

11 <http://paedsurg.ukzn.ac.za/Staff/DRRinusWiersma.aspx>

12 Rinus Wiersma, *OvoTesticular Disorder of Sex Development in Southern Africa*, Thesis to obtain the degree of Doctor from the Erasmus University Rotterdam (2011), p. 107, http://repub.eur.nl/pub/30680/111222_Wiersma,%20Rinus.pdf

13 *ibid*, p. 106

The textbook “**Paediatric Surgery: A Comprehensive Text for Africa, Volume II**”¹⁴ of which “each chapter is written by an acknowledged international expert and an African counterpart who has extensive experience” (Foreword by Heinz Rode, Emeritus Professor **Red Cross War Memorial Children’s Hospital**, University of Cape Town, p. xi), in chapter “99. Disorders Of Sex Development” also advocates early gonadectomies on intersex children diagnosed with CAIS and PAIS, justified by an alleged¹⁵ high cancer risk (p. 578):

*“For patients with CAIS or PAIS raised female, the testes should be removed to prevent malignancy in adulthood. The availability of estrogen-replacement therapy allows for the option of **early removal at the time of diagnosis.**”*

- **IGM 2: “Feminising” Genital Surgeries:** The 2012 combined 8th biannual conference of the Pan African Association of Paediatric Surgeons (PAPSA) and the **South African Association of Paediatric Surgeons (SAAPS)**, hosted by the **University of Cape Town**,¹⁶ featured in its programme¹⁷ during its Urology session a contribution titled “*Banana-split Clitoroplasty & feminising genitoplasty in disorders of sex differentiation in children*” (p. 7).

Also the textbook “**Paediatric Surgery: A Comprehensive Text for Africa, Volume II**”¹⁸ advocates (p. 577):

“[...] clitoroplasty [...] in infancy starting from 6 months of age [...]”

Accordingly, at the Department of Paediatric Surgery, **University of KwaZulu-Natal**, Durban, “feminising” genital surgeries are recommended on young intersex children:¹⁹

“When is it an appropriate time for cosmetic surgery?”

*In some DSD patients where the gender for raising the child has been determined early, the condition will allow and indeed is **best managed with early ‘cosmetic surgery’** e.g. among the XY-DSD with testosterone insensitivity.[25] In the XX-DSD some time should be allowed to ensure that medication to correct the biochemical defect and stop further androgenization is established before clitoral reduction surgery is commenced.[26,27]”*

While for the above diagnoses at **KwaZulu-Natal**, Durban, no treatment statistics were disclosed, from 1984-2006 on children diagnosed with “*Ovo Testicular DSD*” alone the following “feminising” genital surgeries were done:²⁰

*“There were **30 patients** who were old enough to know their gender [i.e. 7–8 years, cf. p. 120] and had **successful clitoro- and labioplasties**. Only one 13-year old child is unsure about her gender, but the remaining patients were all confidently female. **In 16 patients vaginoplasties were done be-***

14 Emmanuel Ameh, Stephen Bickler, Kokila Lakhoo, Benedict Nwomeh, Dan Poenaru (eds.), *Paediatric Surgery: A Comprehensive Text for Africa, Volume II*, http://www.global-help.org/publications/books/help_pedsurgeryafricavolume02.pdf

15 Actual malignancy risks: CAIS 0.8%, PAIS 15%, see 2016 CRC UK NGO Report (p. 63, Table 1), http://intersex.shadowreport.org/public/2016-CRC-UK-NGO-Zwischengeschlecht-Intersex-IGM_v2.pdf

16 <http://www.papsa2012.com/organizing-comittee/>

17 <http://www.papsa2012.com/wp-content/uploads/2012/03/PAPSA-Programme-WEB5.pdf>

18 Emmanuel Ameh, Stephen Bickler, Kokila Lakhoo, Benedict Nwomeh, Dan Poenaru (eds.), *Paediatric Surgery: A Comprehensive Text for Africa, Volume II*, http://www.global-help.org/publications/books/help_pedsurgeryafricavolume02.pdf

19 Rinus Wiersma, *Ovo Testicular Disorder of Sex Development in Southern Africa*, Thesis to obtain the degree of Doctor from the Erasmus University Rotterdam (2011), p. 27, http://repub.eur.nl/pub/30680/111222_Wiersma,%20Rinus.pdf

20 *ibid*, p. 113

tween 8 -15 years, some by the gynaecologists. Two children were 10 and 13-years of age at their last review had an external opening vagina, and three children have had vaginoplasty and still required dilatation.”

- **IGM 1: “Masculinising” Genital Surgeries:** The 2012 combined 8th biannual conference of the Pan African Association of Paediatric Surgeons (PAPSA) and the South African Association of Paediatric Surgeons (SAAPS), hosted by the **University of Cape Town**,²¹ featured a **“Pre Conference Course ‘Operative Urology Workshop’”** including hypospadias **“live surgeries”** at the **Red Cross War Memorial Children’s Hospital**, Cape Town,²² and with contributions by Alastair Millar and John Lazarus (Department of Paediatric Surgery, University of Cape Town – the latter also co-lectured on *“hypospadias”* at the *“Parallel Session: Urology”* during the regular Conference Programme).²³

Accordingly, at the Department of Paediatric Surgery, **University of KwaZulu-Natal**, Durban, also “feminising” genital surgeries are performed on young intersex children (numbers only of children diagnosed with *“Ovo Testicular DSD”* 1984-2006):²⁴

“Thirty-one patients raised as males had a correction of chordee as a first procedure. These patients had normal to small for age penises, but all had a hypospadias with tethering of the penis to the scrotum.

The Duckett ‘transverse island flap’ urethroplasty using the prepuccial mucosa without hair follicles and few sweat gland has been the procedure of choice to reconstruction of the neo-urethral tube along the length of the ventral penis.[14] Fourteen such ‘transverse island flap’ procedures have been done where there has been insufficient urethral length. In three patients where the urethral plate was longer, the ‘tubularised incised plate’ (TIP) urethroplasties have been done.[15]”

- **Repeated Forced Genital Exams and Photography** are also common place in South Africa, see e.g. the experience of Nthabiseng Mokoena at **Chris Hani Baragwanath Hospital (Johannesburg)**:²⁵

“Once every month I would have to travel to Soweto for “healthcare”.

That was the one of the worst experiences of my life, I would have to undress and the doctor would bring his medical students into the room to give them a lecture on “disorders of sexual development”, with me as the exhibition. I stopped seeing this doctor, I used painkillers to cope with the pain and only had the courage to see another doctor only 6 years after that experience. I later realised that this is a typical experience for most intersex persons in the country, you either had surgery as a child and had to deal with the consequences by yourself for the rest of your life or if you were lucky enough to escape surgery as a child, you had to deal with the difficulty of accessing healthcare as an adult.”

See also the **typical pictorial examples** of forced medical display and genital photography of intersex humans from a 1970 Durban (Natal) zoology thesis **“INTERSEX IN FOUR SOUTH AFRICAN RACIAL GROUPS IN DURBAN”** on p. 18–19.

21 <http://www.papsa2012.com/organizing-comittec/>

22 <http://www.papsa2012.com/pre-and-post-congress-courses/urology/>

23 <http://www.papsa2012.com/wp-content/uploads/2012/03/PAPSA-Programme-WEB5.pdf>

24 Rinus Wiersma, *Ovo Testicular Disorder of Sex Development in Southern Africa*, Thesis to obtain the degree of Doctor from the Erasmus University Rotterdam (2011), p. 121, http://repub.eur.nl/pub/30680/111222_Wiersma,%20Rinus.pdf

25 <http://intersexday.org/en/remembering-sally-south-africa/>

c) Examples of SA University Children's Clinics advocating & perpetrating IGM

The “South African Association of Paediatric Surgeons (SAAPS)” lists on its home-page 7 “Paediatric Surgery Centers”²⁶ – all of them perpetrating IGM practices:

- **University of Cape Town**, hosted the 2012 combined 8th biannual conference of the Pan African Association of Paediatric Surgeons (PAPSA) and the South African Association of Paediatric Surgeons (SAAPS)²⁷ featuring a “*Pre Conference Course ‘Operative Urology Workshop’*” including hypospadias “*live surgeries*” at the **Red Cross War Memorial Children's Hospital**, Cape Town²⁸ and with contributions by Alastair Millar and John Lazarus (Department of Paediatric Surgery, University of Cape Town – the latter also co-lectured on “*hypospadias*” at the “*Parallel Session: Urology*” during the regular Conference Programme).²⁹ John Lazarus further co-chaired the “15th Paediatric Urology/ Surgery Teaching Program” in Mauritius (2013), where he was involved in 11 hypospadias surgeries and 2 orchidopexies,³⁰ and in a lecture listed “*hypospadias*” under “*Common problems in Paediatric Urology*”.³¹
- **Witwatersrand University, Johannesburg (Chris Hani Baragwanath Hospital)**: A case study presented by endocrinologist Debbie Gordon describes an adolescent diagnosed with “*True hermaphroditism (TH), or OT-DSD (ovotesticular disorder of sexual development)*”:³²
“*At the age of two, a hypospadias had been repaired.*”
“*[At 14,] a blind-ending vagina was removed. The scrotum was explored and a large L sided ovotestis and small R sided testis were removed.*”
- **Free State University, Bloemfontein**: Host of the “*Paediatric Urology Workshop – Bloemfontein 2011*”,³³ where Professor Schalk Wentze, Head of the Department of Urology, participated in “*live surgery*” including 2 “*Hypospadias repair[s]*” on children aged 1 year and 8 years (the latter also submitted to “*Laparoscopy*” [gonadectomy and/or orchidopexy] for “*UDT [Undescended Testes] + dysgenesis*”), and conference chair Dr Freddie Claassen (Chief Specialist Urology) together with John Lazarus (University of Cape Town) co-chairing urology lectures including
“*1. The ‘hypospadias cripple’ patient - what are the options?*”
“*2. Investigation of non-palpable testes.*”
“*3. The management of recurrent urethral fistula after hypospadias repair*”
- **University of Stellenbosch (Tygerberg Hospital, Cape Town)**: Together with the “South African Urological Society” co-host of the “*Paediatric Workshop: Urology, Radiology and Nephrology – South Africa 2012*”,³⁴ with “*live surgery*” including 2 “*Hypospadias repair[s]*” on children aged 1 year and 3 years. “*As acting head of the Urology Unit, Dr Andre van der Merwe organized the operative session patients, and the equipment, with the able assistance of his team.*”

26 <http://www.paediatricsurgery.co.za/paediatric-surgery-centers/>

27 <http://www.papsa2012.com/organizing-committee/>

28 <http://www.papsa2012.com/pre-and-post-congress-courses/urology/>

29 <http://www.papsa2012.com/wp-content/uploads/2012/03/PAPSA-Programme-WEB5.pdf>

30 see p. 4, <http://www.kindcutsforkids.net/files/Mauritius%20November%202013.pdf>

31 see slide 3, <http://www.uom.ac.mu/MedicalUpdate/files/2013/Update11November2013/commonProblemsInPaedriatic.pdf>

32 45th SEMDSA CONGRESS 2010: Poster presentations (p. 31), <http://www.jemdsa.co.za/index.php/JEMDSA/article/download/174/193>

33 <http://www.kindcutsforkids.net/files/South%20Africa%202011.pdf>

34 <http://www.kindcutsforkids.net/files/South%20Africa%20November%202012.pdf>

- **University of KwaZulu-Natal, Durban** – see above b), IGM 3, IGM 2, and IGM 1.
- **University of Pretoria:** On 7 July 2016 the SABC aired a segment on hypospadias on the show, “Morning Live”, titled “*Urologist suggests early corrective operation for hypospadias*”. The show featured **Dr Kabo Ijane** (Urology Hospital in Pretoria), strongly advocating for early surgery: “*[I]t is important that a corrective operation is done early in life.*”³⁵ “*The [Urology] hospital works closely with The Department of Urology at the University of Pretoria’s Medical School [...].*”³⁶
- **Walter Sisulu University, Mthatha, Eastern Cape:** The “Urology” of the “Department of Paediatric Surgery” of the “East London Hospitals Complex (ELHC)” offers surgeries for “Hypospadias” and “Disorder of Sex Development”: “**Hypospadias is one of the most common conditions treated here.**”³⁷ “*The Department of Paediatric Surgery is also affiliated with the Walter Sisulu University [...].*”³⁸

d) Infant Victims of “Muti” Genital Mutilations submitted to IGM practices

As Sally Gross (Intersex South Africa) noted, also infant victims of “Muti” mutilations (excision of body parts for incorporation as ingredients into traditional medicine and concoctions) concerning the genitalia have been submitted to IGM practices as “therapy”, including at the **Chris Hani Baragwanath Hospital (Johannesburg)**.³⁹

e) Harmful Practices on Intersex Children outside Health Care Settings

In its 2016 Concluding Observations for *Nepal* (CRC/C/NPL/CO/3-5, paras 41–42), this Committee already recognised severe stigma and bullying of intersex children in school leading to children not being able to complete education as constituting a harmful practice on intersex children outside health care settings. For example Nthabiseng Mokoena reports the **stigma of her intersex birth** leading to her mother for a long time not being able to talk to her about being intersex:⁴⁰

“[I]n African culture, unfortunately, the birth of a child is the mother’s responsibility and if there is something ‘wrong’ with the child the blame goes to the mother, and so she felt extremely isolated after giving birth to me. And she said to me: ‘All that I ever ask is that you not feel the same pain that I went through after giving birth to you, and it’s not that I was ashamed that I gave birth to a child like you it’s because people put me in that position.’”

From a news report (also cited in the 2016 ACHPR NGO Report):⁴¹

*“In 2010 a **principal at a school in Ga-Ntatelang village near Kuruman undressed a six-year-old child, who had ambiguous genitalia [...]**”*

35 <http://www.sabc.co.za/news/a/fd8213004d67b9b0a35eef4b5facb1b5/Urologist-suggests-early-corrective-operation-for-hypospadias-20160707> Iranti-org: “Press Release - The Urology Hospital in Pretoria operates in violation of human rights norms”, http://www.iranti-org.co.za/content/Press_Releases/2016/Urology-Hospital-Pretoria-Intersex.pdf Video of the show “Morning Live”, <https://www.youtube.com/watch?v=gig4QqurdTo>

36 <http://www.urology.co.za/index.php/urolocare/>

37 <http://eyabantwana.co.za/pediatric-surgical-service/departement-of-paediatric-surgery/urol-ogy/>

38 <http://eyabantwana.co.za/pediatric-surgical-service/departement-of-paediatric-surgery/>

39 Sally Gross: “Notes on Intersexuality and Ethical Issues Raised by the Standard Protocol of Treatment for Intersexed Infants and Children”, paras 13 and 9, <http://www.intersex.org.za/index.php/en/publications/medical-ethics-and-practice/59-notes-on-intersexuality-and-ethical-issues-raised-by-the-standard-protocol-of-treatment-for-intersexed-infants-and-children>

40 <http://www.interfaceproject.org/transcript-nthabiseng-mokoena>

41 <http://mg.co.za/article/2012-06-28-gentle-mans-brutal-murder-turns-spotlight-on-intolerance>

There are even reports of **selective infanticide of intersex newborns** justified by cultural beliefs, e.g. again in the John Taolo Gaetsewe district:⁴²

*“We interviewed 90 midwives ... 88 of them said **when a child with ambiguous genitalia is born they will twist the child’s neck, killing it, because it is a product of a bewitched or cursed family,**’ Griqua said.*

The mother would be told that her child was stillborn.”

f) SA Doctors and Government consciously dismissing Human Rights Concerns

Both South African doctors and the Government are admittedly aware of the human rights implications of IGM practices, but still refuse to take action accordingly. For example Rinus Wiersma, Department of Paediatric Surgery, **University of KwaZulu-Natal**, Durban, on one hand explicitly theorises:⁴³

*“Decisions must be taken in the context of the **rights of the child** as outlined in the constitution of the country, and must be in the **best interests of the child**. In South Africa, for example, this is contained in Section 28 of *The Bill of Rights of the South African Constitution*.”*

On the other hand (as also noted in the 2016 ACHPR NGO Report), in practice surgeon Wiersma immediately follows up the above quote with these contradicting **“Recommendations”**:⁴⁴

*“Of primary importance is an understanding of the physical and psychological dilemmas that face these individuals in the future. **Informed consent with complete disclosure** of all risks, complications, follow-up and potential for impaired sexual function **must be provided to parents of children with ambiguous genitalia.**”*

Also the **South African Government** has been repeatedly made aware of the human rights violations inflicted by IGM practices **since at least 1999**.⁴⁵ In 2004, according to news reports the **South African Human Rights Commission (SAHRC)** explicitly considered legislation to eliminate IGM practices:^{46 47}

*“**A law on corrective surgery** for children with ambiguous genitals - intersex children - was **under consideration**, the SA Human Rights Commission said yesterday.”*

However, unfortunately these “considerations” never resulted in anything tangible, and to this day also in South Africa there are **no legal or other protections** in place to ensure the rights of intersex children to physical integrity, autonomy and self-determination, nor to prevent non-consensual, medically unnecessary, irreversible surgery and other harmful treatments a.k.a. IGM practices, but **public University clinics continue to perpetrate IGM with impunity, directly funded by the State party.**

42 *ibid.*

43 Rinus Wiersma, *Ovo Testicular Disorder of Sex Development in Southern Africa*, Thesis to obtain the degree of Doctor from the Erasmus University Rotterdam (2011), p. 132, http://repub.eur.nl/pub/30680/111222_Wiersma,%20Rinus.pdf

44 *ibid.*

45 Sally Gross (Intersex South Africa): “Report on SA Human Rights Commission workshop”, <http://www.intersex.org.za/index.php/en/publications/engaging-with-the-sa-human-rights-commission/58-report-on-sa-human-rights-commission-workshop>

46 Wendell Roelf: “Intersex children must be protected from temptation of parents to ‘fix’ them surgically”, Cape Times 01.12.2004, <https://web.archive.org/web/20041226061403/http://www.capetimes.co.za/index.php?fSectionId=271&fArticleId=2329017>

47 News24 (Nov 30 2004 06:14:21:507PM): “Intersex legislation considered”, archived: <http://www.intersex.org.za/index.php/en/publications/engaging-with-the-sa-human-rights-commission/57-intersex-legislation-considered>

2. The Treatment of Intersex Children in South Africa as a Harmful Practice and Violence

a) Harmful Practice ⁴⁸

Article 24 para 3 CRC calls on states to abolish harmful “traditional practices prejudicial to the health of children”. While the initial point of reference for the term was the example of Female Genital Mutilation/Cutting (FGM/C), the term consciously wasn’t limited to FGM/C, but meant to include all forms of harmful, violent, and/or invasive traditional or customary practices.⁴⁹

The Committee has repeatedly considered IGM as a harmful practice, and the CRC/CEDAW Joint General Comment No. 18/31 on harmful practices as applicable.⁵⁰

Harmful practices (and inhuman treatment) have been identified by intersex advocates as the **most effective, well established and applicable human rights frameworks** to eliminate IGM practices and to end the impunity of the perpetrators.⁵¹

The **Joint General Comment No. 18 “on harmful practices”** “*call[s] upon States parties to explicitly prohibit by law and adequately sanction or criminalize harmful practices, in accordance with the gravity of the offence and harm caused, provide for means of prevention, protection, recovery, reintegration and redress for victims and combat impunity for harmful practices*” (para 13).

Particularly, the Joint General Comment further underlines the need for a “**Holistic framework for addressing harmful practices**” (paras 31–36), including “**legislative, policy and other appropriate measures that must be taken to ensure full compliance with [state parties’] obligations under the Conventions to eliminate harmful practices**” (para 2), as well as

- “Data collection and monitoring” (paras 37–39)
- “Legislation and its enforcement” (paras 40–55), particularly:
- “adequate civil and/or administrative legislative provisions” (para 55 (d))
- “provisions on **regular evaluation and monitoring**, including in relation to implementation, enforcement and follow-up” (para 55 (n))
- “**equal access to justice, including by addressing legal and practical barriers to initiating legal proceedings, such as the limitation period, and that the perpetrators and those who aid or condone such practices are held accountable**” (para 55 (o))
- “equal access to **legal remedies and appropriate reparations in practice**” (para 55 (q)).

48 For a more extensive version, see *2016 CRC UK Thematic NGO Report*, p. 55–56, http://intersex.shadowreport.org/public/2016-CRC-UK-NGO-Zwischengeschlecht-Intersex-IGM_v2.pdf

49 UNICEF (2007), *Implementation Handbook for the Convention on the Rights of the Child*, at 371

50 CRC/C/CHE/CO/2-4, 4 February 2015, paras 42–43: http://tbinternet.ohchr.org/_layouts/treatybodyexternal/Download.aspx?symbolno=CRC/C/CHE/CO/2-4&Lang=En

CRC/C/CHL/CO/4-5, 2 October 2015, paras 48–49, http://tbinternet.ohchr.org/_layouts/treatybodyexternal/Download.aspx?symbolno=CRC%2fC%2fCHL%2fCO%2f4-5&Lang=en

51 Daniela Truffer, Markus Bauer / *Zwischengeschlecht.org*: “Ending the Impunity of the Perpetrators!” Input for Session 3: “Human Rights Standards and Intersex People – Progress and Challenges - Part 2” at “Ending Human Rights Violations Against Intersex Persons.” OHCHR Expert Meeting, Geneva 16–17.09.2015, online: http://StopIGM.org/public/S3_Zwischengeschlecht_UN-Expert-Meeting-2015_web.pdf

Last but not least, the Joint General Comment explicitly stipulates: “Where **medical professionals** or government employees or civil servants **are involved or complicit in carrying out harmful practices**, their status and responsibility, including to report, should be seen as an **aggravating circumstance in the determination of criminal sanctions or administrative sanctions such as loss of a professional licence or termination of contract**, which should be preceded by the issuance of warnings. **Systematic training** for relevant professionals is considered to be an effective preventive measure in this regard.” (para 50)

Thus, **IGM practices in South Africa** – as well as the **complete failure of the state party to enact appropriate legislative, administrative, social and educational measures** to eliminate them and to ensure effective access to remedies and redress – clearly violate Article 24 CRC, as well as the CRC/CEDAW Joint General Comment No. 18/31 on harmful practices.

b) Violence against Children ⁵²

Similarly, the Committee has also considered IGM practices as violence against children, and Art. 19 and the General Comment No. 13 also offers strong provisions to combat IGM practices.

3. Lack of Legislative Provisions to Ensure Protection from IGM Practices, Impunity of the Perpetrators

Article 24 para. 3 of the Convention in conjunction with the CRC/CEDAW Joint General Comment No. 18/31 “on harmful practices” (2014) underline state parties’ obligations to “**explicitly prohibit by law and adequately sanction or criminalize harmful practices**” (JGC 18/31, para 13), as well as to “**adopt or amend legislation with a view to effectively addressing and eliminating harmful practices**” (JGC 18/31, para 55), and specifically to ensure “**that the perpetrators and those who aid or condone such practices are held accountable**” (JGC 18/31, para 55 (o)).

Also Article 19 of the Convention calls upon states to “**take all appropriate legislative, administrative, social and educational measures to protect the child from all forms of physical or mental violence**”, and the General Comment No. 13 “The right of the child to freedom from all forms of violence” (2011) stipulates that state parties “**ensur[e] absolute prohibition of all forms of violence against children in all settings and effective and appropriate sanctions against perpetrators**” (GC 13, para 41 (d)).

Accordingly, with regards to IGM practices, and referring to Article 24 para 3 and the CRC/CEDAW Joint General Comment No. 18/31, this Committee already explicitly recognised the obligation for State parties to “**ensure that no-one is subjected to unnecessary medical or surgical treatment during infancy or childhood, guarantee bodily integrity, autonomy and self-determination to children concerned**”, as well as to “[u]ndertake investigation of incidents of surgical and other medical treatment of intersex children without informed consent and **adopt legal provisions in order to provide redress to the victims of such treatment, including adequate compensation**”.⁵³

However, to his day and **against better knowledge the South African government refuses to even discuss, let alone enact appropriate legislative measures** to

52 For a more extensive version, see 2016 CRC UK Thematic NGO Report, p. 57, http://intersex.shadowreport.org/public/2016-CRC-UK-NGO-Zwischengeschlecht-Intersex-IGM_v2.pdf

53 CAT/C/CHE/CO/7, 14 August 2015, para 20: http://intersex.shadowreport.org/public/CAT_C_CHE_CO_7-Concl-Obs-Switzerland-2015_G1520151.pdf

effectively eliminate IGM practices, nor to **address the factual impunity of IGM perpetrators**.

Worse, **South African government bodies**, while repeatedly having been made aware of the harm done by the practice, are **actively shielding IGM perpetrators** by refusing to take action to outlaw and adequately sanction the practice.

This situation with the **South African government** ignoring the ongoing practice while continuing to **protect and fund the perpetrators** is clearly not in line with **South Africa's obligations** under the Convention and CRC/CEDAW Joint General Comment No. 18/31.

4. Obstacles to Redress, Fair and Adequate Compensation

Article 24 para. 3 of the Convention in conjunction with the CRC/CEDAW Joint General Comment No. 18/31 “on harmful practices” clearly stipulate the right of victims of IGM practices to **“equal access to legal remedies and appropriate reparations”** (JGC 18/31, para 55 (q)), and specifically to ensure that *“children subjected to harmful practices have equal access to justice, including by addressing legal and practical barriers to initiating legal proceedings, such as the limitation period”* (JGC 18/31, para 55 (o)).

Article 19 of the Convention and the General Comment No. 13 “The right of the child to freedom from all forms of violence” also stipulate the right of victims to **“effective access to redress and reparation”** (GC 13, para 41 (f)), **“including compensation to victims”** (GC 13, para 56).

However, also in **South Africa** the **statutes of limitation** prohibit survivors of early childhood IGM practices to call a court, because persons concerned often **do not find out** about their medical history until much later in life, and **severe trauma** caused by IGM Practices often prohibits them to act in time even once they do.⁵⁴ So far there was no case of a victim of IGM practices succeeding in going to a South African court.

The **South African government** so far refuses to ensure that non-consensual unnecessary IGM surgeries on minors are recognised as a form of **genital mutilation**, which would formally prohibit parents from giving “consent”. In addition, the state party **refuses to initiate impartial investigations**, as well as data collection, monitoring, and disinterested research.

This situation is not in line with the **South Africa's** obligations under the Convention.

54 Globally, no survivor of early surgeries **ever** managed to have their case heard in court. All relevant court cases (3 in Germany, 1 in the USA) were either about surgery of adults, or initiated by foster parents.

B. Conclusion: South Africa is Failing its Obligations towards Intersex People under the Convention on the Rights of the Child

The surgeries and other harmful treatments intersex people endure cause severe physical and mental pain and suffering. Doctors perform the surgery for the discriminatory purpose of making a child fit into societal and cultural norms and beliefs, although there is plenty of evidence of the suffering this causes. The State party is responsible for these violations constituting a harmful practice, violence against children, and torture or at least ill-treatment, perpetrated by publicly funded doctors, clinics, and universities, as well as in private clinics, all relying on money from the mandatory health insurance, and public grants. Although in the meantime the pervasiveness of IGM practices is common knowledge, South Africa nonetheless fails to prevent these grave violations, but allows the human rights violations of intersex children to continue unhindered.

Thus **South Africa is in breach of its obligation to take effective legislative, administrative, judicial or other measures to prevent harmful practices** (Art. 24 para. 3 in conjunction with CRC/CEDAW Joint General Comment No. 18/31 “on harmful practices”), as well as of its obligations under Articles 2, 3, 6, 8, 12, 16, 19, 23, 24.1, 34, 36, and 37 of the Convention on the Rights of the Child.⁵⁵

Also in South Africa, victims of IGM practices encounter severe obstacles in the pursuit of their **right to redress, fair and adequate compensation, including the means for as full rehabilitation as possible**.

Further the state party’s efforts on **education and information regarding the human rights aspects of IGM practices in the training of medical personnel** are grossly insufficient with respect to the treatment of intersex people.

55 See *2016 CRC UK Thematic NGO Report*, p. 53–58, http://intersex.shadowreport.org/public/2016-CRC-UK-NGO-Zwischengeschlecht-Intersex-IGM_v2.pdf

C. Recommendations

*The Rapporteurs respectfully suggest that the Committee recommends the following measures to the South African Government with respect to the treatment of intersex children (based on the Committee's previous recommendations to **Switzerland** and **Ireland**):*

Intersex Persons

The Committee remains seriously concerned about cases of medically unnecessary and irreversible surgery and other treatment on intersex children, without their informed consent, which can cause severe suffering, and the lack of redress and compensation in such cases.

In the light of its joint general comment No. 18 (2014) and No. 31 of the Committee on the Elimination of Discrimination against Women on harmful practices, the Committee recommends that the State party:

- (a) Ensure that no-one is subjected to unnecessary medical or surgical treatment during infancy or childhood, adopt legislation with a view to guarantee bodily integrity, autonomy and self-determination to children concerned, and provide families with intersex children with adequate counselling and support;**
- (b) Undertake investigation of incidents of surgical and other medical treatment of intersex children without informed consent and adopt legal provisions in order to provide redress to the victims of such treatment, including adequate compensation; and,**
- (c) Educate and train medical, psychological and education professionals on intersex as a natural bodily variation and on the consequences of unnecessary surgical and other medical interventions for intersex children.**

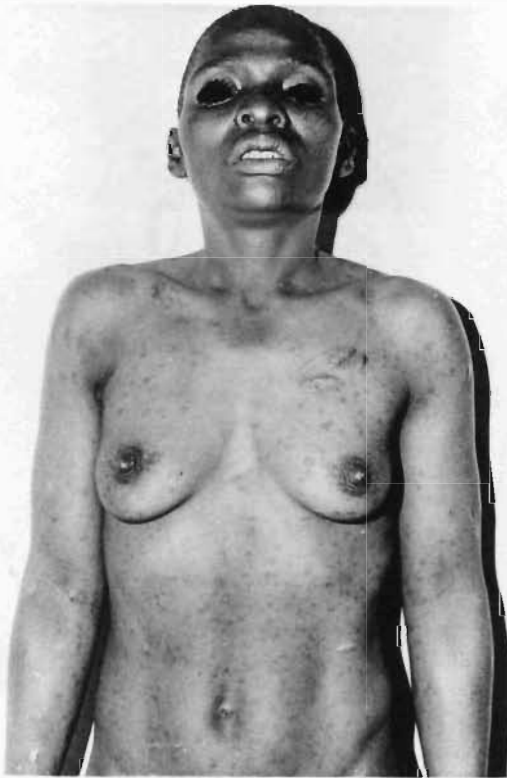

Fig. 55: Breast development in a hermaphrodite.

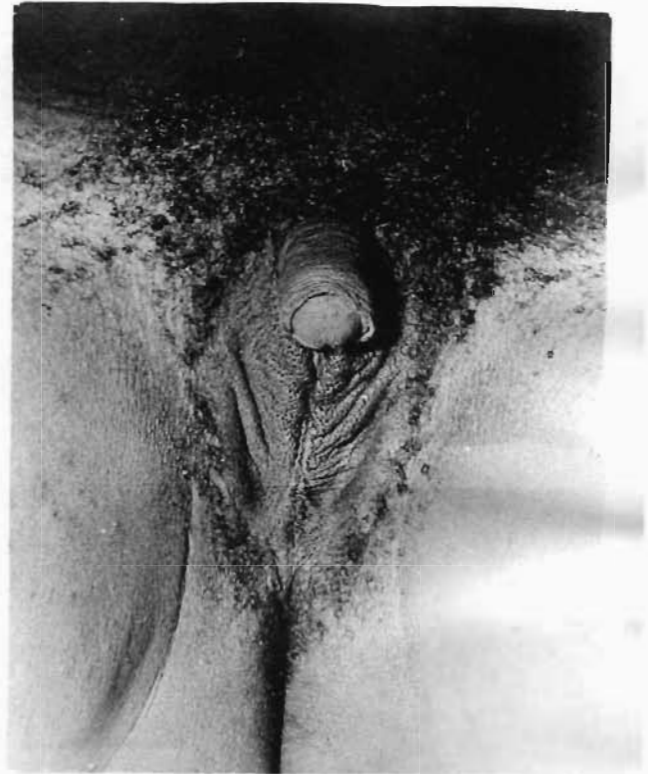

Fig. 56: Ambiguous external genitalia




Fig. 57: Mosaic karyotype of (a) 46,XX and (b) 46,XY cell lines.

Medical Display and Genital Photography

Source: Hatherley James Grace, B.Sc. (Natal), "INTERSEX IN FOUR SOUTH AFRICAN RACIAL GROUPS IN DURBAN. Thesis submitted in partial fulfilment of the requirements for the degree of Master of Science in the Department of Zoology of the University of Natal, December 1970", p. 206

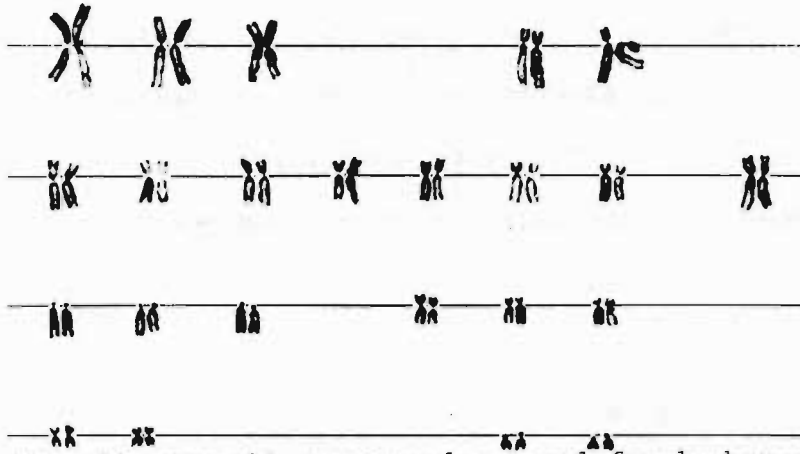


Fig. 66: Case 28, apparently normal female karyotype

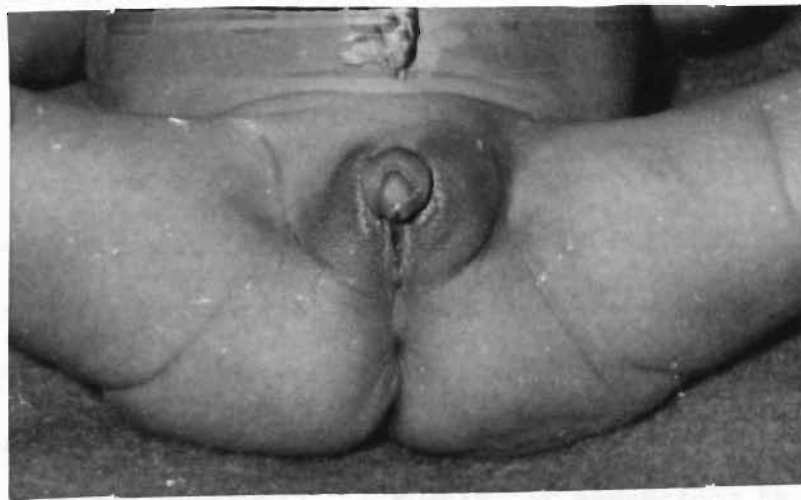

Fig. 66: Case 29, intersexual genitalia.

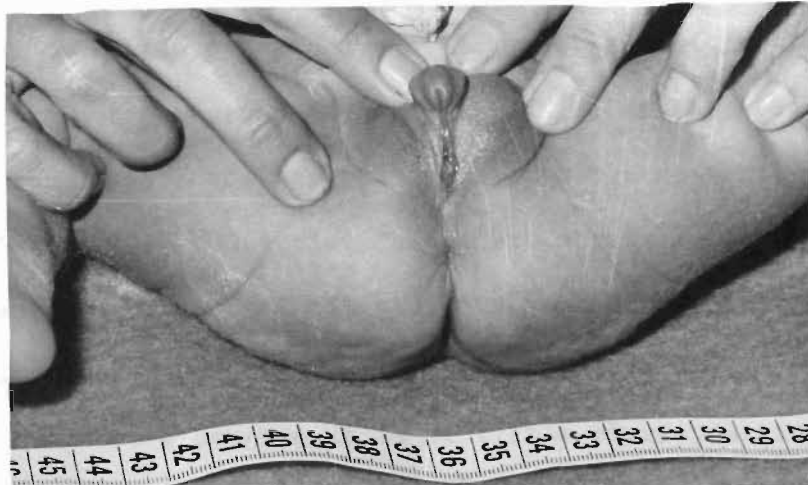


Fig. 67: Case 29, showing hypospadiac urogenital meatus. Left gonad is in the inguinal hernia.

Medical Display and Forced Genital Photography

Source: Hatherley James Grace, B.Sc. (Natal), "INTERSEX IN FOUR SOUTH AFRICAN RACIAL GROUPS IN DURBAN. Thesis submitted in partial fulfilment of the requirements for the degree of Master of Science in the Department of Zoology of the University of Natal, December 1970", p. 210



STOP
Intersex
Genital
Mutilation!

StopIGM.org / Zwischengeschlecht.org